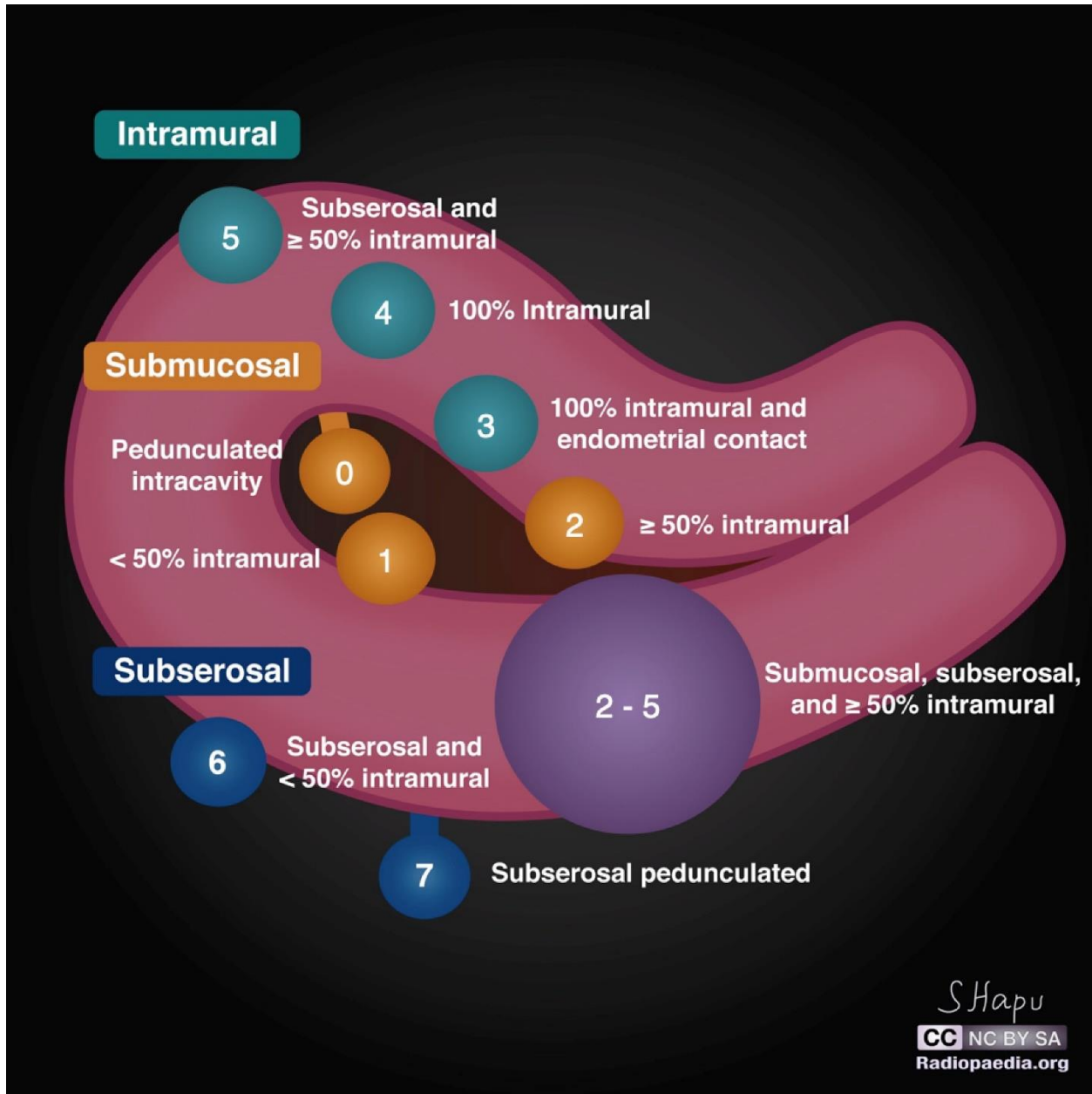


Fibroid Classification



Case courtesy of Sachi Hapugoda, Radiopaedia.org, rID: 62908

<https://radiopaedia.org/?lang=us>

From the case <https://radiopaedia.org/cases/62908?lang=us>